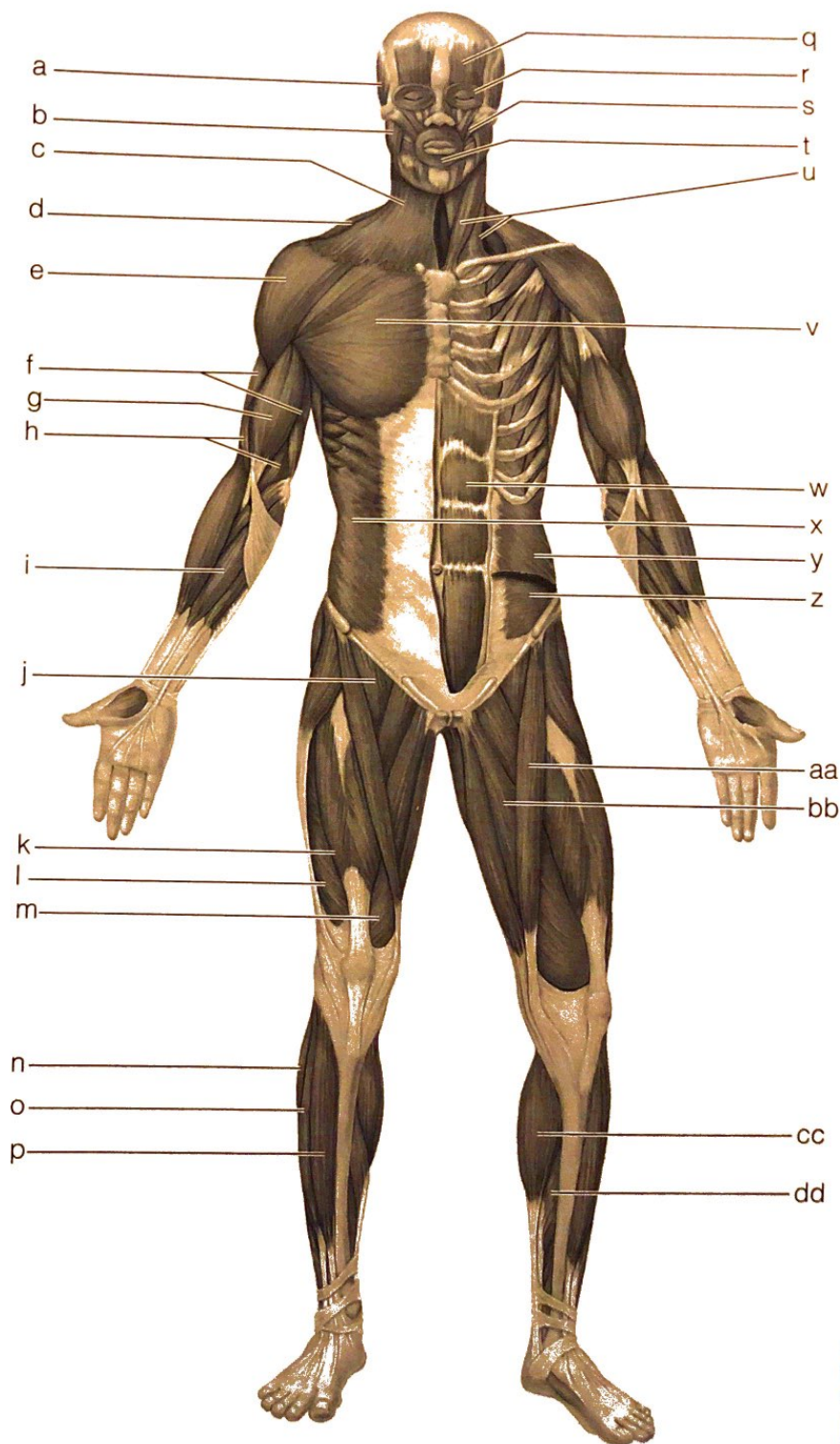


General Review: Muscle Recognition

6. Identify the lettered muscles in the diagram of the human anterior superficial musculature by matching each letter with one of the following muscle names:

- _____ 1. orbicularis oris
- _____ 2. pectoralis major
- _____ 3. external oblique
- _____ 4. sternocleidomastoid
- _____ 5. biceps brachii
- _____ 6. deltoid
- _____ 7. vastus lateralis
- _____ 8. frontalis
- _____ 9. rectus femoris
- _____ 10. rectus abdominis
- _____ 11. sartorius
- _____ 12. platysma
- _____ 13. flexor carpi radialis
- _____ 14. orbicularis oculi
- _____ 15. gastrocnemius
- _____ 16. masseter
- _____ 17. trapezius
- _____ 18. tibialis anterior
- _____ 19. adductors
- _____ 20. vastus medialis
- _____ 21. transversus abdominis
- _____ 22. fibularis longus
- _____ 23. iliopsoas
- _____ 24. temporalis
- _____ 25. zygomaticus
- _____ 26. triceps brachii



- _____ 27. brachialis
- _____ 28. extensor digitorum longus
- _____ 29. internal oblique
- _____ 30. soleus

7. Identify each of the lettered muscles in this diagram of the human posterior superficial musculature by matching the letter to one of the following muscle names:

- _____ 1. gluteus maximus
- _____ 2. semimembranosus
- _____ 3. gastrocnemius
- _____ 4. latissimus dorsi
- _____ 5. deltoid
- _____ 6. semitendinosus
- _____ 7. trapezius
- _____ 8. biceps femoris
- _____ 9. triceps brachii
- _____ 10. external oblique
- _____ 11. gluteus medius
- _____ 12. flexor carpi ulnaris
- _____ 13. extensor carpi ulnaris
- _____ 14. extensor digitorum
- _____ 15. extensor carpi radialis
- _____ 16. sternocleidomastoid
- _____ 17. adductor magnus
- _____ 18. soleus

